Ruptured Anterior Cruciate Ligament (ACL)

Drs. Foster & Smith Educational Staff

The knee is prone to a number of injuries as any football player will tell you. One of the most common knee injuries in dogs is a ruptured cruciate ligament.

Knee anatomy

The knee is a joint that is formed by three bones: Femur (the long bone extending down from the hip); Tibia (the bone between the knee and ankle); and Patella (the kneecap). These bones are joined together by a number of ligaments, which are tough fibrous bands of tissue. Two ligaments crisscross in the joint from the femur to the tibia and are called cruciate ligaments (cruciate means cross). The one towards the front of the leg is called the anterior cruciate ligament and the one crossing behind it is the posterior cruciate ligament. These ligaments prevent the ends of the femur and tibia from moving back and forth across each other.

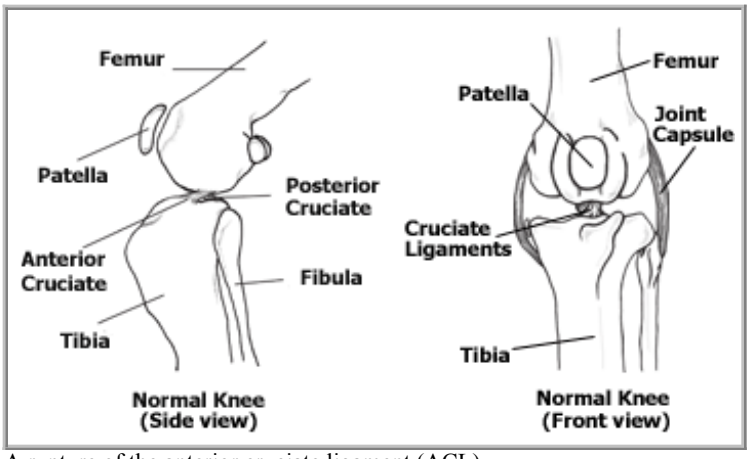

A rupture of the anterior cruciate ligament (ACL)

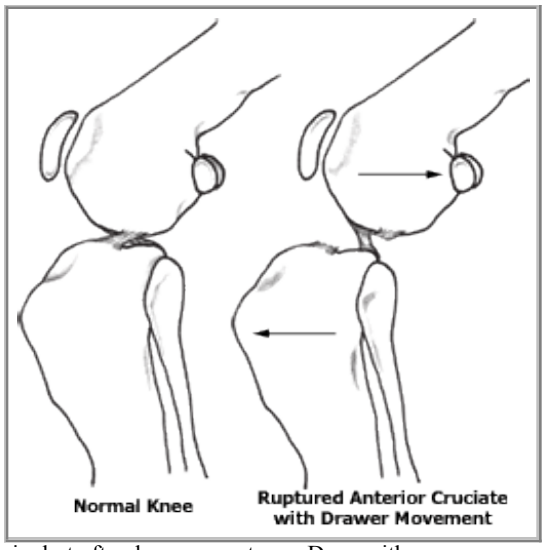

When the anterior cruciate ligament ruptures (is torn), the joint becomes unstable and the femur and tibia can move back and forth across each other. The anterior cruciate ligament is commonly torn when the dog twists on his hind leg. The twisting motion puts too much tension on the ligament and it tears. This often occurs if the dog slips on a slippery surface, makes a sudden turn while running, or is hit by a car. Obesity puts too much weight on the knee and overweight dogs tend to have more occurrences of ruptured cruciate ligaments. It appears that in most dogs with the problem, the ACL slowly degenerates and becomes weaker until it ruptures, without any sudden injury. Certain breeds appear to be at increased risk of ACL degeneration and include the Newfoundland, Labrador Retriever, Rottweiler, Bichon Frise, St. Bernard, and others. Many dogs with a degenerating ACL will have the condition in both knees. In small breed dogs, a luxating patella may predispose them to a ruptured anterior cruciate ligament.

Symptoms of a ruptured cruciate ligament

Dogs who have ruptured their cruciate ligament will appear suddenly lame, and usually hold the foot of the affected leg off the ground. The knee may become swollen. In time, the dog may start to use the leg again, but often lameness returns. Dogs with a degenerating ACL may also show some pain, and there may be some swelling in the joint.

Diagnosis of a ruptured cruciate ligament

The diagnosis of a ruptured cruciate ligament is made through observing abnormal movement of the joint. A veterinarian will place one hand around the femur and one around the tibia in a precise manner. By applying pressure on the knee, the veterinarian will feel the bones move abnormally in what is called a 'drawer sign.' It is called that because the movement of the femur in relation to the tibia is similar to pulling and pushing in the drawer of a cabinet. If an animal is in a lot of pain, or very nervous, the muscles near the knee may be so tense that they prevent the drawer movement from occurring. If a veterinarian suspects a ruptured cruciate

*Unauthorized use of any images, thumbnails, illustrations, descriptions, article content, or registered trademarks of **Foster & Smith, Inc.** is strictly prohibited under copyright law. Site content, including photography, descriptions, pricing, promotions, and availability are subject to change without notice. These restrictions are necessary in order to protect not only our copyrighted intellectual property, but also the health of pets, since articles or images that are altered or edited after download could result in misinformation that may harm companion animals, aquatic life, or native species.*

ligament in a dog but cannot elicit the drawer sign, the dog may be heavily sedated to relax the muscles and then re-examined for the drawer sign. Many dogs with a ruptured cruciate ligament will have swelling on the inside aspect of the knee, and this is called a medial buttress. Radiographs are commonly performed to better assess the amount of arthritis that may be present.

Treatment of a ruptured cruciate ligament

If the ligament is completely torn, the dog (especially a large dog) is generally treated with surgery. There are several different methods used to repair the knee joint when an anterior ligament is torn. Some entail using synthetic suture material, or a portion of adjacent fibrous tissue to basically re-create the ligament. The suture or tissue is made to extend from the outside lower portion of the femur to the inside upper portion of the tibia. After the surgery, the dog must be strictly confined for 2 weeks. By day 10 after surgery, most dogs touch the toe of the affected leg to the ground and will start bearing minimal weight on the leg. Once the dog has reached this point, it is often very difficult to keep the dog quiet until complete healing has taken place. The dog generally has to be restricted to only leash walking for a minimum of 4-6 more weeks; the exact amount of time depends upon the extent of the injury and the corrective procedure performed. This is extremely important to prevent the surgical correction from tearing. The veterinarian's instructions regarding exercise during the recovery period should be followed very carefully.

Another surgery that may be performed is the tibial plateau leveling osteotomy (TPLO). In this procedure, a portion of the tibia is cut, moved, and reattached to a different portion of the tibia using plates and screws. By changing the conformation of the tibia, the joint is stabilized. This is a technically difficult surgery but it has shown to produce excellent results, often with less arthritis. This surgery is especially recommended for dogs over 50 pounds in weight. The recovery period is similar to that with the other surgical procedures.

The third procedure that may be used is the tibial tuberosity advancement (TTA). This is another surgery in which a different portion of the tibia is cut, and allowed to heal at a different angle to change the mechanical stresses on the joint. As with the TPLO, this surgery is more complex and it requires special equipment and training.

In some instances, if the cruciate ligament is only partially torn, the animal is older, has medical conditions which could affect healing, or the owners will not be able to keep the dog quiet for a number of weeks after surgery, medical treatment is used. This basically consists of controlling the dog's activity for 8-12 weeks. Swimming and low-impact exercise (walking) may be done on a controlled basis, as instructed by a veterinarian, to keep up muscle strength. If overweight, the dog should be placed on a reduced-calorie diet. Nonsteroidal anti-inflammatory drugs (NSAIDS) such as carprofen, etodolac, meloxicam, deracoxib, buffered aspirin, or other medications are often used to reduce inflammation in the joint and relieve pain. (Do NOT give your cat aspirin unless prescribed by your veterinarian.) Products containing glucosamine, chondroitin, perna mussel, polysulfated glycosaminoglycans, and other chondroprotective agents are often recommended, as well.

If a dog with a ruptured cruciate is not treated, severe degenerative joint disease (arthritis) usually occurs. In addition, because the dog favors the affected leg, he will generally put more weight on the unaffected leg. It is not unusual for the dog to rupture the anterior cruciate ligament on that leg as well because of the increased stress on the leg.

Prognosis

If the dog's exercise is restricted as instructed, and overweight dogs return to normal body weight, the prognosis is good. Depending on the amount of injury to the knee and length of time between the injury and correction of the problem, degenerative joint disease may occur as the pet ages.

*Unauthorized use of any images, thumbnails, illustrations, descriptions, article content, or registered trademarks of **Foster & Smith, Inc.** is strictly prohibited under copyright law. Site content, including photography, descriptions, pricing, promotions, and availability are subject to change without notice. These restrictions are necessary in order to protect not only our copyrighted intellectual property, but also the health of pets, since articles or images that are altered or edited after download could result in misinformation that may harm companion animals, aquatic life, or native species.*