Tooth Resorption in Cats: Feline Oral Resorptive Lesions (FORLs)

Drs. Foster & Smith Educational Staff

Cats are prone to a serious and very painful dental disease called 'tooth resorption.' This condition was previously referred to as 'feline oral resorptive lesions' (FORLs). Various studies have found 28-67% of cats have tooth resorption. Tooth resorption is the most common cause of tooth loss in the cat.

Tooth resorption tends to occur in older cats (over 4 years of age) and may be more common in purebred cats, especially Siamese and Abyssinians.

What is tooth resorption?

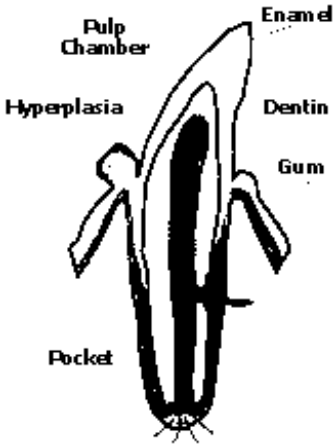

Tooth resorption results in the loss of tooth structure, starting with the outer enamel surface, usually at or below the gumline. The lesions, which are NOT cavities, begin as a loss of tooth enamel and can eventually spread to the dentin and then the pulp canal, which contains the blood vessels and nerves to the tooth. Sometimes, the entire crown of the tooth may be missing.

Tooth resorption is progressive and may be singular or multiple and on the lingual (side where the tongue is) or buccal (side where the cheek is) side of the tooth. Some lesions are readily apparent and others may be hidden under areas of plaque or swollen gums. This is why a cat needs to be anesthetized to determine if such lesions are present: the entire surface of each tooth must be examined.

The lesions most commonly occur in the larger, multi-rooted teeth - the molars and premolars - at the area where the roots diverge. They can also occur in the canine teeth and incisors.

What causes tooth resorption?

The cause of these resorptive lesions is unknown. One theory is that the inflammation caused by plaque may stimulate cells called 'odontoclasts,' which eat away at the enamel of the tooth. Other possible causes include autoimmune disorders, changes in pH in the mouth, viral diseases, or a problem with calcium metabolism.

What signs of disease are associated with tooth resorption?

Resorptive lesions that have eroded through the enamel may be very painful. Cats with oral pain may appear irritable or aggressive, have a change in appetite or food preference, and may have difficulty chewing and eating (food falls from their mouth). Cats with resorptive lesions may show pain when their jaws are touched and may also have increased salivation or oral bleeding.

How are resorptive lesions diagnosed?

Many lesions may be easily visible. However, a dental explorer should be used to examine each tooth above and below the surface of the gum. Any calculus on the teeth needs to be removed before a complete examination can be performed.

Dental radiographs are essential in diagnosing this condition and evaluating the extent of disease. Resorption lesions are graded I-V according to the amount of tooth that is lost with Grade I being mild and Grade V being severe.

How is tooth resorption treated?

Depending upon the stage of resorption, the entire tooth with the roots may be extracted, or only a portion of the tooth is removed.

It is recommended that cats who have a history of tooth resorption should have a prophylaxis (professional dental cleaning) every six months.

Good home dental care is important for cats with tooth resorption. Follow the veterinarian's instructions carefully.

Classification of Tooth Resorption in Cats

Stage I: Loss of enamel only, extending less than 0.5 mm into the tooth.
Stage II: Lesion extends into the dentin.
Stage III: Lesion extends into the pulp canal, but good tooth structure remains

*Unauthorized use of any images, thumbnails, illustrations, descriptions, article content, or registered trademarks of **Foster & Smith, Inc.** is strictly prohibited under copyright law. Site content, including photography, descriptions, pricing, promotions, and availability are subject to change without notice. These restrictions are necessary in order to protect not only our copyrighted intellectual property, but also the health of pets, since articles or images that are altered or edited after download could result in misinformation that may harm companion animals, aquatic life, or native species.*

remains.

Stage IV: Lesion extends into the pulp canal and there is extensive loss of tooth structure.

Stage V: Crown of tooth is missing, but roots are present.

*Unauthorized use of any images, thumbnails, illustrations, descriptions, article content, or registered trademarks of **Foster & Smith, Inc.** is strictly prohibited under copyright law. Site content, including photography, descriptions, pricing, promotions, and availability are subject to change without notice. These restrictions are necessary in order to protect not only our copyrighted intellectual property, but also the health of pets, since articles or images that are altered or edited after download could result in misinformation that may harm companion animals, aquatic life, or native species.*