Aortic Thromboembolism in Cats

Drs. Foster & Smith Educational Staff

Cats with heart disease may develop an aortic thromboembolism, or "saddle thrombus." This is a serious condition in cats in which a thrombus (blood clot) affects the blood flow to the hind legs of the cat.

What is an aortic thromboembolism?
An aortic thromboembolism is a blood clot that generally forms in the heart and then moves down the large artery (aorta) that provides blood to the abdomen and hind legs of the cat. It may help to review some anatomy to understand this disease condition.

The cat's circulatory system is quite similar to that of humans. The heart has four chambers. The two upper chambers are the left and right atria, while the stronger, lower chambers are the right and left ventricles.

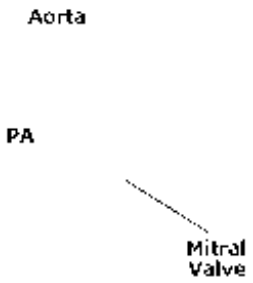

LA	**Left atrium**
LV	**Left ventricle**
PA	**Pulmonary artery**
PV	**Pulmonary vein**
RA	**Right atrium**
RV	**Right ventricle**
VC	**Vena cava**

Blood exits the tissues, travels toward the heart, and enters the right atrium. From there it moves into the right ventricle. The right ventricle pumps blood from the body into the lungs to exchange carbon dioxide (produced by cellular metabolism) for oxygen. Blood, now rich in oxygen, leaves the lungs through the pulmonary vein and enters the left atrium. The left atrium pumps blood to the left ventricle. The left ventricle is the most heavily muscled, and therefore, the strongest of the chambers. The left ventricle pumps blood through the aorta, which supplies the body with blood and oxygen. The aorta extends from the heart along the back of the animal until it reaches the area of the pelvis where it divides into two branches, forming the shape of "Y."

An aortic thromboembolism usually starts as a clot in the left atrium of the cat. The clot forms there when the left atrium is not functioning correctly, as in the case of cardiomyopathy. If the clot dislodges, it moves through the left ventricle and into the aorta, and is called an aortic thromboembolism. The clot moves down the aorta until it reaches the point where the aorta divides into two arteries. If the clot is small, it may enter one of the branches and ultimately lodge in the blood vessel that brings blood to that leg. Otherwise, the clot remains at the split and cuts off blood flow to the two smaller arteries, which provide blood to both hind legs.

What are the symptoms of an aortic thromboembolism in cats?
The signs of an aortic thromboembolism in cats will depend primarily on which blood vessels are blocked, and if the block is total or partial. If the clot enters only one of the branches, then only that hind leg will be involved. If the clot is a true saddle thrombus, it stays at the area where the aorta divides into two, and both hind legs will be affected.

On physical exam, the veterinarian will often hear a heart murmur or abnormal heart sound. Signs of heart failure may be present.

When the hind legs are examined, the pulse is usually very weak or nonexistent. The muscles of the hind leg swell, become hard, and extremely painful. The leg(s) may appear cool to the touch. Usually the tail and ability to urinate are normal. Cats may lose the sense of touch in the affected leg(s) and may be unable to walk. The nails and pads may appear bluish in color. The cat may also show signs of shock. The onset of these signs is usually very rapid.

The rectal temperature is usually low, and the lower the temperature, the poorer the expected outcome.

How is an aortic thromboembolism in cats diagnosed?
The diagnosis of an aortic thromboembolism in cats is made through the history and findings on the physical exam. Radiographs (x-rays) are usually taken of the heart, which is enlarged in almost all cases. Special tests may be performed to assess the actual blood flow through the aorta and vessels.

How is an aortic thromboembolism in cats treated?
Because the prognosis (outlook) for a cat with an aortic thromboembolism is very poor and the condition is so painful, many

*Unauthorized use of any images, thumbnails, illustrations, descriptions, article content, or registered trademarks of **Foster & Smith, Inc.** is strictly prohibited under copyright law. Site content, including photography, descriptions, pricing, promotions, and availability are subject to change without notice. These restrictions are necessary in order to protect not only our copyrighted intellectual property, but also the health of pets, since articles or images that are altered or edited after download could result in misinformation that may harm companion animals, aquatic life, or native species.*

owners will elect to euthanize the cat.

The prognosis is better if only one leg is mildly involved. In these cases, treatment may be attempted and may include pain control, cage rest, and sometimes an anticoagulant in an attempt to prevent further clots from forming. Since most cats with an aortic thromboembolism are also in heart failure, the heart failure is treated as well.

Surgery to remove the clot is seldom performed as it is usually associated with high mortality. A procedure called 'rheolytic thrombectomy' may be used to try to break up the clot. This procedure requires anesthesia and passing a catheter down the aorta. Medications to dissolve the clot have been used but require very strict monitoring and often the cat develops another clot within several months.

Can anything be done to prevent an aortic thromboembolism from forming in cats with heart failure?
Unfortunately, treatments that attempt to prevent the formation of these clots in cats are usually not very effective.

*Unauthorized use of any images, thumbnails, illustrations, descriptions, article content, or registered trademarks of **Foster & Smith, Inc.** is strictly prohibited under copyright law. Site content, including photography, descriptions, pricing, promotions, and availability are subject to change without notice. These restrictions are necessary in order to protect not only our copyrighted intellectual property, but also the health of pets, since articles or images that are altered or edited after download could result in misinformation that may harm companion animals, aquatic life, or native species.*